

Congenital Muscular Torticollis and Positional Plagiocephaly

Alice A. Kuo, MD, PhD,*
Sophie Tritasavit, DPT,[†]
John M. Graham Jr, MD,
ScD[‡]

Author Disclosure
Drs Kuo, Tritasavit, and Graham have disclosed no financial relationships relevant to this article. This commentary does not contain a discussion of an unapproved/investigative use of a commercial product/device.

Educational Gap

The incidence of torticollis is as high as 16% in a normal newborn population. Torticollis is vastly underreported in infants with positional plagiocephaly. Early identification of torticollis and referral to early intervention services by a physical therapist could result in complete correction of torticollis and positional plagiocephaly and prevent the need for cranial orthoses or surgery.

Objectives After completing this article, readers should be able to:

1. Understand the prevalence of congenital muscular torticollis (CMT) and its association with positional plagiocephaly.
2. Counsel parents on the importance of "tummy time" in the treatment of CMT and prevention of positional plagiocephaly.
3. Guide parents on strategies to treat CMT and prevent positional plagiocephaly.
4. Refer appropriately to a physical therapist for treatment of CMT.

Introduction

The term *torticollis* refers to the postural positioning that occurs when the head is twisted and turned to one side. Prenatally acquired congenital muscular torticollis (CMT) is the most common type of torticollis and is due to asymmetric length and/or strength of the sternocleidomastoid (SCM) muscles on each side of the neck. Congenital muscular torticollis is believed to be due to fetal head descent or abnormal intrauterine fetal positioning during the third trimester, resulting in trauma to the SCM muscle and occasional associated deformations of the back, hips, and feet. Alternative, but potentially concomitant, theories of the origin of CMT include fibrosis of the SCM muscle, resulting from venous occlusion due to intrauterine persistent lateral flexion and rotation of the neck, or trauma to the SCM muscle during difficult deliveries.

Differential Diagnosis of Torticollis

Although CMT is the most common type of torticollis, other causes of abnormal posturing of the head and neck should be considered. Sandifer syndrome is a combination of hiatal hernia and abnormal posturing of the head and neck. The abnormal posturing has been attributed to the attempt to decrease the pain of esophagitis, resulting from gastroesophageal reflux and hiatal hernia. In children with this syndrome, after treatment of the hiatal hernia with fundoplication, the torticollis will often resolve itself, with return of normal motion and appearance of the head and neck. Some cases of torticollis are associated with ocular abnormalities, such as weakness of the superior oblique or

lateral rectus muscles or the presence of nystagmus. Surgical correction of extraocular muscles will often result in the resolution of the ocular torticollis. Congenital vertebral anomalies may cause abnormal positioning of the head, such as seen in Klippel-Feil syndrome. Posttraumatic infections and inflammation of adjacent structures, neoplastic conditions, and rare structural and functional neurologic

Abbreviations

CMT: congenital muscular torticollis
SCM: sternocleidomastoid

*Departments of Pediatrics and Internal Medicine, David Geffen School of Medicine at UCLA, Los Angeles, CA.

[†]Early Start Pediatric Physical Therapy, Los Angeles, CA.

[‡]Medical Genetics Institute, Cedars-Sinai Medical Center, Los Angeles, CA.

conditions may also cause torticollis in childhood. Paroxysmal torticollis is an unusual self-limiting condition that consists of intermittent spasms of the SCM muscle, often sporadically involving both sides. Treatment is ineffective and usually resolves by age 2 or 3 years.

Epidemiology, Plagiocephaly Association

The extent to which torticollis is present at birth is not well known, although older studies quote rates of torticollis of less than 1%. Many clinical studies have demonstrated that infants with CMT have an increased incidence of other deformations, such as metatarsus adductus and developmental dysplasia of the hip, to the degree that many authors recommend screening for developmental dysplasia of the hip in children with torticollis. (1) In more recent studies, rates of torticollis of 0.3% to 3.92% have been reported in infants with more severe neck involvement or presence of an SCM muscle tumor. One recent prospective study by Stellwagen et al (2) identified that as many as 16% of newborns have evidence of torticollis at birth, making CMT the most common congenital musculoskeletal abnormality. The increase in multiple births due to advanced fertility treatments has resulted in an increase in CMT incidence. (3)

Several risk factors have been associated with the development of positional plagiocephaly (symmetrical or asymmetrical occipital flattening), including torticollis. After the implementation of the Back to Sleep campaign in 1992, the number of infants with positional plagiocephaly increased markedly. It is commonly believed that supine positioning is the major cause of occipital flattening, but most infants who sleep on their backs do not develop clinically significant occipital flattening. Another theory postulated that the deformation began *in utero* and the congenitally flat area is the surface on which the infant would prefer to lie; however, no correlation between cranial asymmetry at birth and subsequent occipital flattening has been found.

The most common associated finding in infants with positional plagiocephaly is torticollis. In a recent prospective case series, Rogers et al (4) determined that although more than 90% of infants with positional plagiocephaly were noted to have preferential head positioning with head rotational asymmetry (ie, torticollis), only 24% of infants had been previously diagnosed as having or treated for torticollis, indicating that the incidence of torticollis is underreported and underdiagnosed in infants with positional plagiocephaly.

Pathophysiology and Clinical Features of CMT

Examination of the histologic features of affected SCM muscle tissue in CMT patients demonstrates that the muscle has been replaced by dense fibrous tissue. Magnetic resonance imaging studies of affected tissue suggest that CMT may be caused by intrauterine or perinatal SCM muscle compartment syndrome. Ischemia and edema within the SCM muscle compartment can result from flexion with lateral bending and rotation of the head and neck, leading to SCM muscle trauma.

Interstitial fibrosis of the muscle is sometimes palpable as a fusiform fibrous mass or tumor that becomes evident in the first 3 weeks after birth and reaches maximum size by age 1 month. This mass comprises myoblasts, fibroblasts, myofibroblasts, and mesenchyme-like cells that usually mature and differentiate. Myoblasts can be mechanically stimulated to undergo hypertrophy and hyperplasia *in vitro* by intermittent stretching and relaxation, and the proper orientation of the skeletal fibers during myogenesis is maintained by rhythmic contractions. Thus, there is good physiologic justification for early initiation of neck physical therapy to prevent muscle fibrosis. (5)

Clinically, in infants with CMT, the head is typically tilted toward the side of the affected muscle and rotated toward the opposite side (although infants with CMT could have ipsilateral tilt and turn, the differential diagnosis for ipsilateral tilt and rotation should include causes other than CMT, such as congenital vertebral malformation, intracranial tumor, ocular abnormality, infection, or malignant tumor). In CMT, skull and facial asymmetry (in addition to plagiocephaly) may be present. Jaw asymmetry with mandibular hypoplasia may be the first indication that CMT is present, and some mothers notice that infants with CMT have difficulty breastfeeding equally well from both breasts. Ears are asymmetric as well, with the ear on the side of the torticollis, or affected SCM muscle, often smaller and the ear opposite the torticollis displaced forward with the contralateral occipital flattening. The ipsilateral eye is often smaller, and the ipsilateral frontal area flattens as a result of forces from the contralateral parietal occipital flattening (Figure 1).

In addition to facial asymmetry that occurs with CMT, atypical postural and gross motor development results from the persistent head tilt and the infant's perception of his or her environment. Young infants rely on neck-righting responses to manage antigravity movements and generate stabilizing postural control. Congenital muscular torticollis can alter the balanced base of support

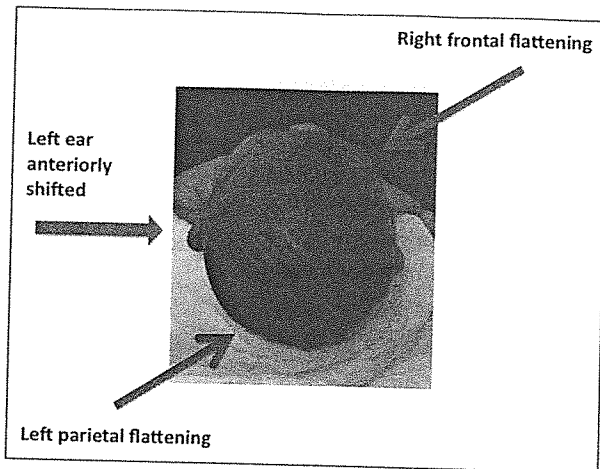


Figure 1. Features of asymmetry related to plagiocephaly in a 4-month-old infant.

or the interaction between deep and superficial muscle groups. The postural abnormalities with infants with CMT include shoulder hiking and lateral side bending on the shortened side. Visual gaze is often oriented toward the side of head turning, further reinforcing the head turning toward the affected side. For infants with developmental delays, plagiocephaly and associated CMT are more common because they are not able to move normally to prevent flattening and the perpetuation of positioning preference.

One associated hypothesis suggests that muscle mechanics are altered in the presence of CMT. The oblique abdominal muscles act as rib stabilizers to assist shoulder girdle and arm stability and function. Shoulder girdle muscles that take their origins from the rib cage require a stable base to function normally. The shoulder girdle and rib cage complex, as the insertion point for many major neck groups, including the clavicular portions of the SCM muscle, contributes to and is affected by poorly coordinated neck muscular activity. (6) On the basis of studies that have found an association between CMT and gross motor delays, another theory suggests that some infants with CMT have hypotonia or low muscle tone, which may have predisposed them to poor intrauterine positioning in the first place.

Other areas of development have been noted to be delayed in some infants with CMT, including problem solving, personal-social interaction, fine motor control, and communication. This effect could be due to the inability of infants with CMT with weaker truncal strength to access their environment and stimulate all the realms of development or another underlying cause of global

developmental delay. In older children and adults with uncorrected CMT, craniofacial deformities may persist, resulting in obvious facial asymmetry. Facial bone asymmetry starts to appear at age 5 years, at which time mandibular and occlusal abnormalities are observed. Deformity of the orbits and maxilla occur at an older age, characterized by the deviation and decreased vertical height on the affected side. The severity of the observed deformities may increase with age. Older children with uncorrected CMT have been noted to have more school problems and require more special education services, although the reason for this association is unclear. The most often identified concern by parents of these children relates to the child's craniofacial appearance and the possibility that he or she will be teased, embarrassed, or otherwise stigmatized because of the condition. It is possible that the child's psychological development is affected by the condition and results in poorer academic performance.

In adults with untreated CMT, the resultant facial asymmetry has sometimes led to attempts at corrective surgery by plastic surgeons or maxillofacial surgeons. These attempts have led to improvement of the facial asymmetry but have rarely resulted in complete correction. Although descriptions of adults with untreated CMT have focused largely on the cosmetic issue of facial asymmetry, extrapolating from the gross motor deficits identified in childhood, one could postulate that adults with untreated CMT have more neck and upper body truncal motor issues, such as weakness or stiffness, which may result in postural or alignment dysfunction and can lead to chronic neck and back issues.

Assessment of CMT in the Primary Care Office

In the primary care office, the child health practitioner should have a high index of suspicion for CMT if the birth history is remarkable for difficult labor or delivery, decreased fetal movement, oligohydramnios, large infant birthweight, breech position, or multiple births (usually affecting the infant who is bottom-most in the uterus). (7) In infants with CMT, the mothers often report that the fetus stayed in one position during the pregnancy and that the back was always on the same side.

On physical examination, the asymmetric sequelae of CMT may be more obvious than the limited range of motion of the neck, particularly in newborns with short necks. Plagiocephaly should be examined from the top of the head and will manifest as a mild flattening of the forehead on one side and of the occiput on the opposite

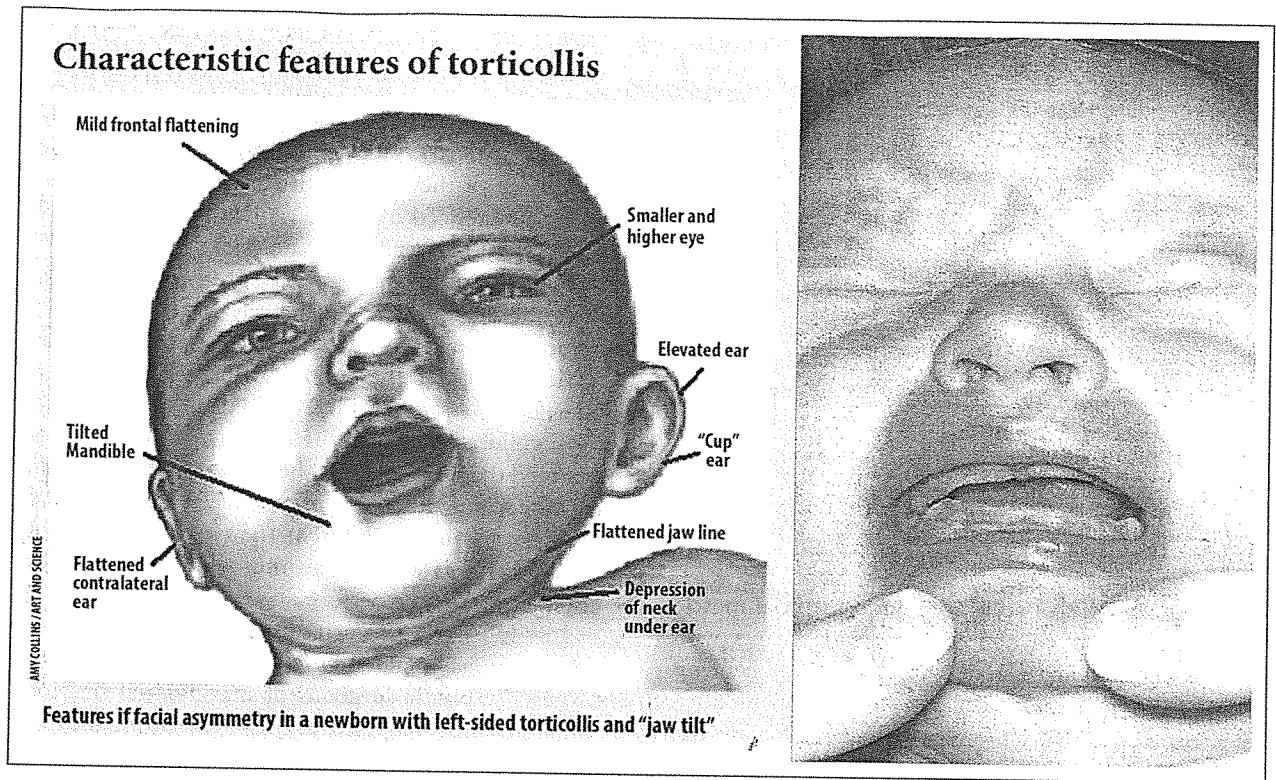


Figure 2. Characteristic features of torticollis. In the picture on the right, the tilting of the lower jaw and gum line are evident on physical examination. In this infant, the tilting of the lower jaw resulted in breastfeeding problems, prompting a visit to the pediatrician. Illustration, left: Copyrighted 2014. Advanstar. 107408:114AT. Image, right: Wall V, Glass R. Mandibular Asymmetry and Breastfeeding Problems: Experience From 11 Cases. *J Hum Lact.* 2006;22(3):328-34. © 2006 by SAGE Publications. Reprinted by Permission of SAGE Publications.

side (Figure 1). Misalignment of the eyes, asymmetry of the ears, flattening of the mandible, and tilting of the lower jaw and gum line (more obvious when the lower gum line is compared with the upper one) are all characteristic features of torticollis (Figure 2).

A small number of infants with CMT may present a diagnostic dilemma if they have bilateral torticollis. These infants present with range of motion impairments on both sides, one side being worse than the other. This diagnosis is often missed because infants with bilateral torticollis usually do not present with an obvious head tilt. In these cases, the discrepancy between right and left is not so large because both are limited. These do not present with obvious plagiocephaly but may present with brachycephaly (flattening and widening of the back of the head) instead. For example, if the infant has limited end-range rotation on both sides, the head will function more or less positioned midline, with perhaps a slight bias toward mildly rotating to one side (Figure 3).

Many child health practitioners miss the diagnosis of CMT because if it appears the child can generally look both ways, it is concluded that they do not have torticollis. In fact, most infants who have torticollis can look both ways to some degree, and the typical impairment in CMT is lacking full range of motion on one side. Child health practitioners should be aware that the range-of-motion norms for infants and children younger than 3 years differ from older children and adults. In older children and adults, full cervical passive range of motion in rotation is 90° (chin to shoulder); however, in children from birth to age 3 years, full passive range of motion in rotation is 100° to 110° (the degree to which someone else can rotate the infant's chin 10° to 20° past the shoulder). In older children and adults, full cervical passive range of motion in lateral flexion is 45°; however, in children between birth and age 3 years, it is between 65° and 75° (in general, the top of the ear should be able to touch the ipsilateral shoulder). If decreased range of motion persists despite several weeks of physical therapy, imaging studies may be considered.

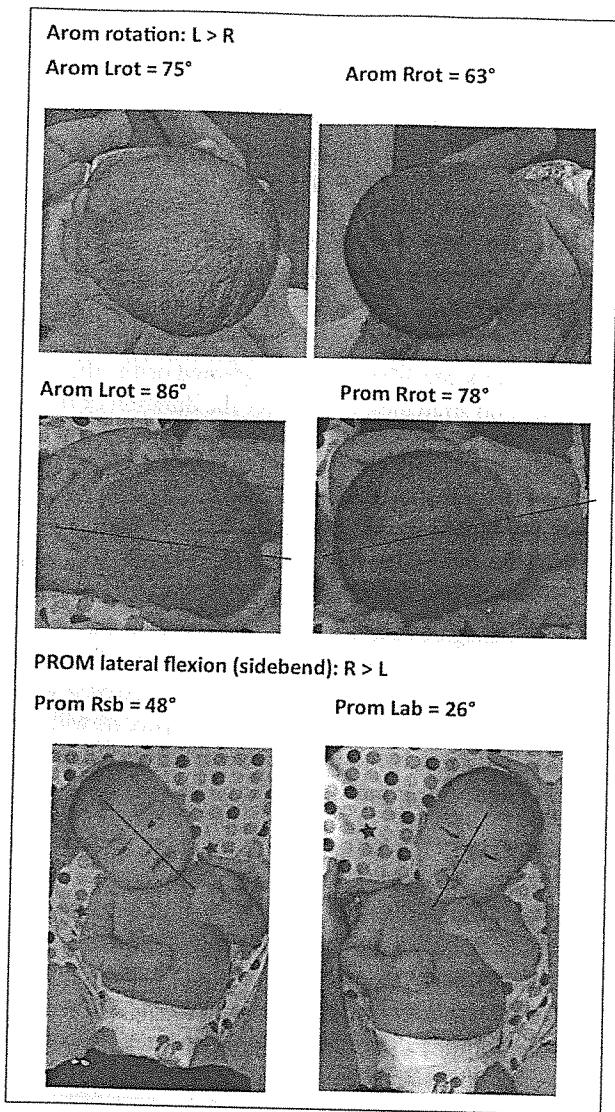


Figure 3. Measurements of a 4-month-old infant with bilateral torticollis greater on the right side than the left side. This infant presents with bilateral impairments in active and passive range of motion. The primary impairments are limited right rotation and left lateral flexion, both of which correlate with restriction of the right sternocleidomastoid muscle. AROM=active range of motion; Lrot=left rotation; Lsb=left side bend; PROM=passive range of motion Rrot=right rotation; Rsb=right side bend.

Initial Management of CMT

Most cases of CMT can be successfully treated conservatively with neck-stretching exercises if diagnosed early enough. These exercises include encouraging the infant to visually regard objects on the less preferred side, placing the infant in the crib so that the door is on the less

preferred side, and holding the infant in such a way so that facing outward is the less preferred side. Most child health practitioners are adept at giving parents such strategies.

Passive neck-stretching exercises are more difficult for child health practitioners to demonstrate to parents and equally difficult for parents to perform successfully at home. The recommendation for effective neck-stretching exercises is to hold each stretch for 30 to 60 seconds, to do 3 repetitions of each stretch, and to do the series of stretches 6 to 8 times a day. Ideally, a stretching period should take approximately 5 to 10 minutes, depending on the cooperative ability of the infant.

Engagement with the infant is crucial for making the stretching exercises effective and enjoyable for the caregiver to perform. Many times, child health practitioners and even some physical therapists hand parents a worksheet of instructions and expect parents to figure out how to do the exercises themselves. Many parents are intimidated by the level of protest of the infant and are concerned that the exercises might be painful. In addition, many parents do not carry out the exercises effectively for fear of injuring the infant. A physical therapist experienced in treating CMT will be able to provide proper guidance so that parents can implement the exercises effectively and safely, while engaging with the child in a positive manner. In the cases of infants who are in child care, nonparental caregivers should be educated to conduct the exercises as well.

These exercises are much easier to perform in younger infants and infants who are engaged with the caregiver performing the exercises. As infants grow bigger and have more desire for independent movement, it can be challenging for parents to perform the exercises effectively and as frequently as recommended. The stretching exercises should be performed to stretch the appropriate SCM muscle and should be based on physical examination to identify the specific muscle impairments, not parents' subjective reports of tilt or turning preferences. However, in cases with unilateral SCM muscle restriction, the unaffected side may have excessive flexibility. For this reason, child health practitioners should not default to instructing parents to perform exercises to both sides of the neck because this could cause a larger discrepancy in the flexibility of the 2 SCM muscles, thus resulting in a more severe tilt. Because of the challenges of teaching parents how to do the exercises appropriately and giving general positioning advice that could possibly worsen plagiocephaly or result in new head deformities, early referral to physical therapy, even for a brief period, is prudent.

It is commonly observed that infants with CMT who are undergoing a stretching exercise program may have periods of regression after observed progress. These periods of regression appear to be associated with growth spurts. It is hypothesized that the SCM muscle on the affected side may not grow or develop at the same rate as on the uninvolved side, creating a risk of return of contracture. During periods of illness, teething, and acquisition of new motor functions, regression to the torticollis posture could also occur.

Child health practitioners in the primary care office must also counsel on sleep positioning and “tummy time” as part of the treatment for CMT. Given the strong association between prone sleep positioning and sudden infant death syndrome, it is advisable to position infants on their backs for sleep, except in cases of prematurity, gastroesophageal reflux, or obstructive sleep apnea. The key to effective management is to position infants in the supine position, with regular variation in the position of the infant’s head to avoid undue flattening.

Encouraging “tummy time” when infants are awake and under observation may help to minimize these differences in normal motor development by strengthening the infant’s neck muscles and facilitating prone motor activities. Because most supine-sleeping infants are unused to viewing their world from the stomach, they need this visual experience to facilitate their motor development. Giving infants adequate “tummy time” while they are awake is also important to facilitate development of head turning while prone as a key protective mechanism in case the infant turns from supine to prone during sleep. Infants with CMT may have a more difficult time with “tummy time” because of slower gross motor development or overall neck muscle tightness and/or weakness. Parents should be counseled to encourage “tummy time” despite infant protests and put infants in a prone position frequently throughout the day for as short as 1 to 2 minutes at the beginning.

Parents who are concerned about head positioning may inquire about various sleep positioners or other positioning or pillow products on the market. Often, these are shaped like donuts and claim to “take the pressure off of the flat spot so your baby’s head can round out as it grows.” Although the Food and Drug Administration and the Consumer Product Safety Commission have warned against the use of infant sleep positioners because of suffocation risk, use of these products inherently misses the point that infants should be spending awake hours in the prone position under adult supervision. In addition, many parents now use car seats that

also serve as infant carriers, many of which fasten directly into strollers and swings without having to remove the infant from the seat, resulting in infants who spend prolonged periods in one position. For infants at risk for CMT or plagiocephaly, car seats should be used only for safety reasons in moving vehicles rather than convenience.

Referral to Physical Therapy

Early intervention is crucial for successful treatment of both CMT and resulting positional plagiocephaly. The earlier infants are identified and treated with effective stretches and strategies, the shorter the duration of treatment necessary to achieve full range of motion of the neck and resolution of the plagiocephaly. The goal is to avoid expensive or invasive interventions, such as cranial orthotics (helmets) or surgery. Several studies have documented the effectiveness of physical therapy in treating CMT and plagiocephaly and avoidance of cranial orthotics or surgery (Figure 4).

The challenge of the primary care office in effectively treating CMT is the inability to quantitate progress with stretches and strategies by parents. Often, parents will not disclose that they are not doing the exercises as frequently (or at all) as recommended by the child health practitioner, or parents do not want to subject their young infant to exercises and think that waiting until the infant is older or bigger is better.

Early referral to a physical therapist can institute effective stretching of the affected SCM muscle by a trained and experienced professional. In addition to ensuring that the infant is getting effective stretching for at least

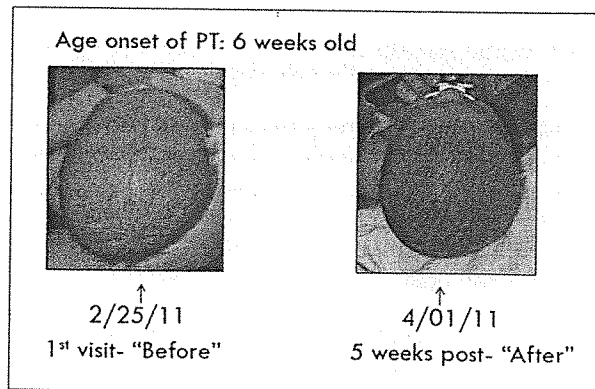


Figure 4. Correction of plagiocephaly with positioning techniques in a 6-week-old infant who was identified and referred to an infant specialist physical therapist. In 5 weeks, significant cosmetic improvement is achieved without the use of a cranial orthotic.

some period, the physical therapist can also demonstrate and teach the caregiver how to perform the exercises so that the exercises at home are more effective as well. In addition, given the likelihood of additional motor delays associated with the diagnosis of CMT, involvement of a physical therapist can address these issues as well. Child health practitioners should try to identify a physical therapist who has experience working with infants. General physical therapists who work primarily with adults or even pediatric physical therapists who tend to work with school-aged children with sports injuries or neurologic problems may not have the expertise to treat CMT in infants.

If CMT persists after 6 months of physical therapy, then additional workup should be considered to evaluate for other potential causes, such as congenital vertebral malformations. Such a workup may include anteroposterior and lateral plain radiographs of the cervical spine and the lateral skull, ophthalmologic examination, and magnetic resonance imaging of the cervical spine (as well as renal ultrasonography and echocardiography if congenital vertebral anomalies are being considered).

Botulinum Toxin Injections and Surgical Treatment of SCM Muscles

Botulinum toxin (Botox) has been used to enhance the effectiveness of stretching on the side of the contracture and allow strengthening of overstretched and weakened muscles on the opposite side of the neck. In severe cases of CMT that are refractory to conservative management with stretching exercises or cases of CMT that were identified or treated in older infants or toddlers, surgical intervention of the SCM muscles may be necessary. Surgery is indicated if symptoms persist after age 1 year despite conservative treatment. An alternative criterion for surgical intervention is the presence of residual deficits in rotation range of greater than 15° of rotation after at least 6 months of controlled manual exercises. Surgical techniques to lengthen tight SCM muscles include unipolar release, bipolar release, endoscopic release, and subperiosteal lengthening. Postoperative physical therapy consisting of range-of-motion exercises is recommended after surgical release of the SCM muscles.

Cranial Orthotics and Other Devices

For children with CMT whose lateral tilt does not resolve with exercises alone, 2 treatment adjuncts exist: tubular orthosis for torticollis collar and elastic therapeutic tape. These therapy tools provide increased sensory feedback

to the infant when he or she tilts in the preferred direction, thus prompting a neuromuscular response to correct for the tilt. Neither therapy tool should be used until it is determined by a physical therapist that the child is demonstrating age-appropriate signs of motor readiness to respond to it optimally.

Some infants with CMT have coexisting deformational plagiocephaly severe enough to warrant use of a cranial remolding orthosis. The duration of treatment with a cranial remolding orthosis could be longer if the torticollis has not resolved and the infant has residual limitations in cervical range of motion. However, until recently, many parents had difficulty getting cranial orthotics covered by insurance because of lack of appropriate billing codes and the misperception that plagiocephaly was a cosmetic (and not medical) condition. The average cost of a cranial remolding orthosis is several thousand dollars, and not infrequently, infants will require more than one orthosis as the head grows during the time of remolding. The use of cranial orthoses for the treatment of plagiocephaly remains somewhat controversial in both overall effectiveness and cost-effectiveness of this intervention. No prospective randomized controlled trials have yet been conducted comparing the efficacy of cranial orthoses to repositioning and physical therapy.

Summary

- On the basis of observational studies, child health practitioners in primary care settings should consider the diagnosis of congenital muscular torticollis (CMT) in infants with risk factors from birth history for intrauterine malpositioning or constraint (C).
- On the basis of observational studies, CMT is often associated with other conditions, including positional plagiocephaly and gross motor delays from weakened truncal muscles and/or lack of head control in early infancy (C).
- On the basis of observational studies, child health practitioners should counsel parents that infants should be on their stomachs frequently whenever they are awake and under direct adult supervision to develop their prone motor skills (C).
- On the basis of consensus, early identification of CMT (with or without positional plagiocephaly) and prompt referral to a physical therapist experienced in the treatment of CMT should be considered to avoid more costly or invasive treatments, such as cranial orthoses or surgery (D).

ACKNOWLEDGMENTS. The authors would like to thank Mina Kang, MD, and Christopher Thrash, MD for their thoughtful review of the manuscript.

References

1. von Heideken J, Green DW, Burke SW, et al. The relationship between developmental dysplasia of the hip and congenital muscular torticollis. *J Pediatr Orthop.* 2006;26(6):805-808
2. Stellwagen L, Hubbard E, Chambers C, Jones KL. Torticollis, facial asymmetry and plagiocephaly in normal newborns. *Arch Dis Child.* 2008;93(10):827-831
3. Littlefield TR, Kelly KM, Pomatto JK, Beals SP. Multiple-birth infants at higher risk for development of deformational plagiocephaly. *Pediatrics.* 1999;103(3):565-569
4. Rogers GF, Oh AK, Mulliken JB. The role of congenital muscular torticollis in the development of deformational plagiocephaly. *Plast Reconstr Surg.* 2009;123(2):643-652
5. Graham JM Jr. Congenital muscular torticollis. In: *Recognizable Patterns of Human Deformation.* 3rd ed. Philadelphia, PA: Elsevier; 2007:130-140.
6. Hylton N. Infants with torticollis: the relationship between asymmetric head and neck positioning and postural development. In: Karmel-Ross, ed. *Torticollis: Differential Diagnosis, Assessment and Treatment, Surgical Management and Bracing.* New York, NY: Haworth Press; 1997: 91-117.
7. Littlefield TR, Kelly KM, Pomatto JK, Beals SP. Multiple-birth infants at higher risk for development of deformational plagiocephaly, II: is one twin at greater risk? *Pediatrics.* 2002; 109(1):19-25

Parent Resources from the AAP at HealthyChildren.org

- English: <http://www.healthychildren.org/English/health-issues/conditions/head-neck-nervous-system/Pages/Positional-Skull-Deformities-and-Torticollis.aspx>
- English: <http://www.healthychildren.org/English/ages-stages/baby/Pages/Positional-Skull-Deformities-in-Infants-Audio.aspx>
- English: <http://www.healthychildren.org/English/health-issues/conditions/head-neck-nervous-system/Pages/Head-Tilt.aspx>
- Spanish: <http://www.healthychildren.org/spanish/health-issues/conditions/head-neck-nervous-system/paginas/head-tilt.aspx>