

Streptococcal Pharyngitis: Guidelines, Treatment Issues, and Sequelae

Stan L. Block, MD, FAAP

The American Academy of Pediatrics¹ along with the Infectious Diseases Society of America² have recently published new guidelines regarding the management of streptococcal pharyngitis. Our office has reviewed them and has confirmed that most of our own current approaches to Group A Streptococcal (GAS) pharyngitis are harmonious. But within our daily practice, I still see a few areas of minor contention with these guidelines that need to be expanded or tweaked.

As usual for this time of year, our office is in the midst of a winter season swarming with children who have streptococcal pharyngitis. However, I have also noticed in the last few years that a few unique physical findings have been associated either concomitantly with or post-treatment from streptococcal pharyngitis. Improving one's ability to recognize and manage the etiology of these other occasional extra-pharyngeal findings will likely improve office care in most general pediatric practices.

Stan L. Block, MD, FAAP, is Professor of Clinical Pediatrics, University of Louisville, and University of Kentucky, Lexington, KY; President, Kentucky Pediatric and Adult Research Inc.; and General Pediatrician, Bardstown, KY.

Address correspondence to Stan L. Block, MD, FAAP, via email: sblockmd@hotmail.com.

Disclosure: Dr. Block has no relevant financial relationships to disclose.

doi: 10.3928/00904481-20131223-04

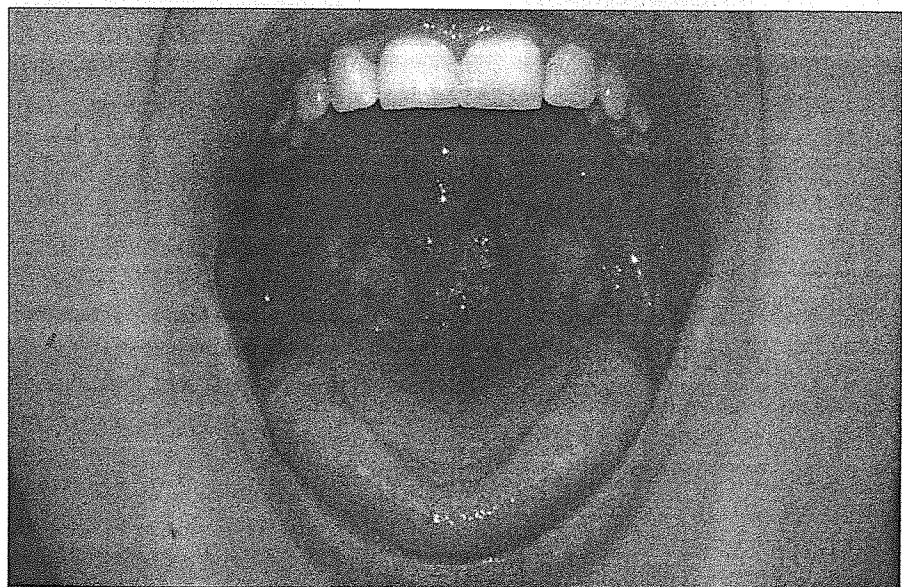


Figure 1. A 15-year-old white girl with exudative tonsillitis, anterior cervical lymphadenitis, and fever.

All images courtesy of Stan L. Block, MD, FAAP

STREPTOCOCCAL PHARYNGITIS

GAS is the primary antibiotic-treatable cause of pharyngitis; nearly all other causes of pharyngitis are viral and, consequently, self-limited. In a typical, office-based general pediatric practice, approximately 20% to 30% of significant pharyngitis cases throughout the year are caused by Group A streptococcus.³ For instance, during a 15-month period in 2012 to 2013 among patients aged 12 months to 20 years, 33% of more than 8,000 tests in our rural Kentucky patients were positive for GAS on a rapid antigen-detection test. Nearly all of the tested patients typically had a history of pharyngitis. Consistent with most aspects of the 2013 AAP pharyn-

gitis guidelines, most of these patients also had either notable physical findings of anterior cervical lymph node swelling (which was often tender), fever, and/or redness of the tonsils or palatine fossa. By contrast, the more classic exudative tonsillitis, such as that seen in **Figure 1**, was not all that common among these patients.

Our office uniformly and customarily uses the immunoassay rapid antigen detection test (ADT), not the culture method, when initially testing for pharyngitis in pediatric patients. We have found our current ADT to be more than 98.5% accurate in our laboratory technician's hands when compared with a backup testing via the gold standard of a refer-

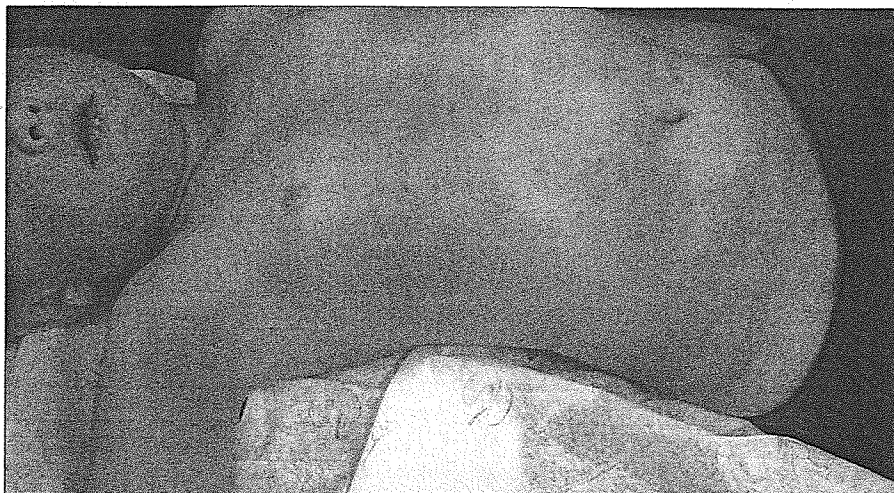

Figure 2. A 7-year-old boy who had typical strep positive pharyngitis along with the classic rash of scarlet fever in appearance and distribution.

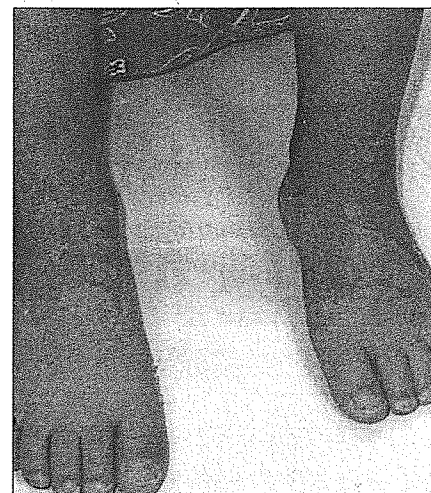


Figure 3. A 15-month-old black boy with typical peeling of feet 1 week after a scarlet fever rash.

ence laboratory testing on blood agar culture plates. The 2013 AAP Red Book³ and the IDSA² recommend backup routine culture testing if your office ADT is negative; however, some experts recommend a backup culture only if the ADT is less than 90% sensitive.^{2,4} Subsequently, this winter, our practice deleted routine additional costly culture testing in patients with a negative ADT, but a practice should only consider this approach once you have documented very high sensitivity of your ADT.

In our experience with in-office streptococcal culture technique over the past few decades, the ADT has provided a much better point-of-care service and appears highly cost-effective. ADT results are available in 10 minutes (versus 1 to 2 days); allow for real-time and nearly instant prescribing when positive (versus 1 to 2 days); and avoids most of the logistical and medico-legal issues of 1- to 2-day-later nurse call-backs and checking for weight-based dosing and drug hypersensitivities. It also avoids the worrisome practice used by some offices of initiating and prescribing a 5- or 10-day course of antibiotics before the culture results return in a few days. On the other hand, watchful waiting for 1 to 2 days until culture results are available defeats much of the primary purpose of prescribing antibiotics for GAS.

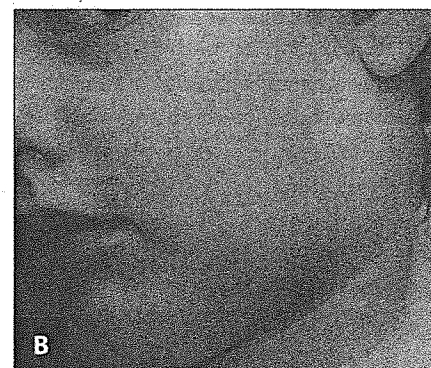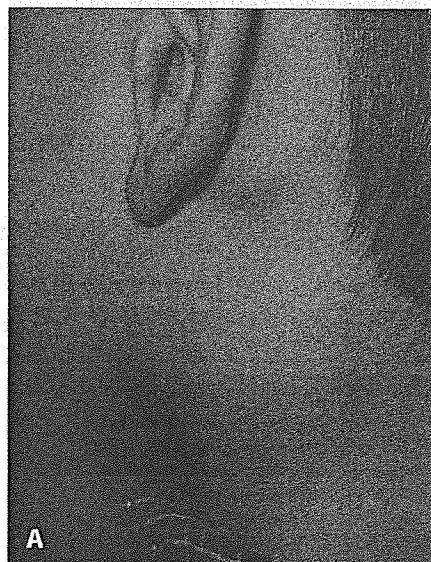


Figure 4. (A) An isolated finding of posterior cervical 3-cm and retroauricular 2-cm lymphadenitis in a 4-year-old white boy without pharyngitis. (B) A 17-month-old white girl who had low grade fever, irritability, and an isolated finding of 4-cm anterior cervical lymphadenitis. Her Group A streptococcal antigen detection test was positive.

We concur with the 2013 AAP guidelines in that antibiotic treatment of pharyngitis should only be prescribed for children with a positive strep test, with extremely rare exceptions.

CONTROVERSIAL ISSUES WITH 2013 AAP GUIDELINES

Although we generally only tested patients who had typical reddened pharynx or tonsils (+/- exudates), tender or enlarged anterior cervical nodes, or fever, a few exceptions to the 2013 AAP guideline rules of testing prevailed in our practice as follows:

- We did not test those who had classic herpangina ulcers, herpetic gingivitis or stomatitis, or hand-foot-mouth syndrome. However, we occasionally found children who had two simultaneous illnesses — a typical viral upper respiratory infection or wheezing along with the usual symptomatic pharyngitis — who were also positive for GAS. We rarely tested patients with croup or hoarseness, except for those with cervical lymphadenitis or classic findings of GAS pharyngitis, including those with palatine petechiae. Therefore, when evaluating children with pharyngitis, one

must exercise some clinical judgment and allow for the rare possibility of two concomitant, unrelated illnesses when appropriate.

- We were more likely to perform an ADT for GAS in children with lower-grade physical findings when they had a sibling who had a very recently documented strep pharyngitis.

- Although we still performed an ADT, we nearly always treated children, regardless of the test findings, who had classic scarlet fever rash with or without concomitant pharyngitis (Figure 2). Occasionally, these children had “surgical scarlet fever” caused by a *S. aureus* lesion, and were treated accordingly. Classic scarlet fever rash consisted of a fine maculopapular, sandpaper rash that was always distributed at least in the groin region, and usually also found in the axilla, elbow crease, neck, and abdomen. Interestingly, this rash rarely ever spreads to the back. Possibly, children with scarlet fever, no *Staphylococcus* lesion, and a negative ADT had an infection with *Arcanobacterium* instead. And rarely, some of the strep-negative children with typical scarlet fever rash would later be discovered to have infectious mononucleosis. We also warned these each of these families about the high likelihood of peeling hands, feet (Figure 3), or groin area within the next week or so in order to prevent their future unnecessary alarm or office visit.

- Most children with any notable isolated findings of acute isolated cervical lymphadenitis were tested for GAS. We do not often merely assume that lymphadenitis is always caused by *Staphylococcus aureus*, *Bartonella*, atypical mycobacterium, or mono. Two examples of children with posterior and anterior cervical lymphadenitis without any signs or symptoms of pharyngitis, but who still had a positive ADT of the pharynx are shown in Figures 4A and 4B, respectively. Both children responded dramatically to a 10-day course of amoxicillin

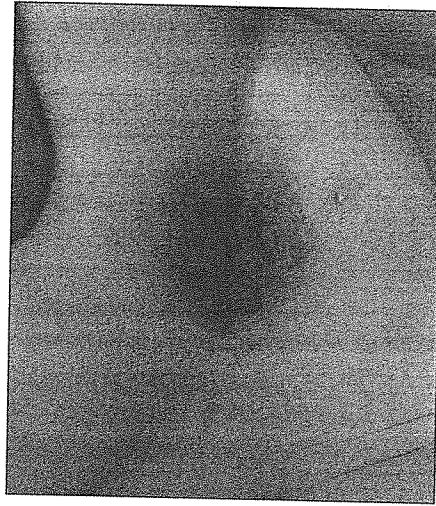


Figure 5. A 5-year-old white boy with a 2-day history of pharyngitis and 101° F fever, who also incidentally complained of anal itching, which was associated with some mild bleeding. Streptococcal testing was positive from the pharynx and anus. He responded well to a 10-day course of amoxicillin.

lin antibiotic and did not need empiric treatment for methicillin-susceptible *S. aureus*, or MRSA. A GAS carrier state could not definitely be excluded.

- Our lower-end cutoff age for GAS testing is younger than proposed in the AAP and IDSA guidelines.^{1,2} We rarely test for GAS in children aged younger than 12 months and sparingly test those aged 12 to 24 months. Although GAS pharyngitis does occur in this age group, as I have previously published in three cases,^{5,6} complications such as ARF and peritonsillar abscess are very uncommon as well. In fact in the last 15 months within our same series of symptomatic pharyngitis patients (above), nearly 2% of our positive strep tests were detected in children aged 6 to 24 months.⁷ Although we could not exclude a GAS carrier state, testing in these age groups was primarily performed in those with the more classic findings consistent with strep pharyngitis, those with siblings who had strep, or those attending daycare.

- We have observed several children with purulent conjunctivitis (not just hyperemia) older than 3 years who have had either streptococcal conjunctivitis,

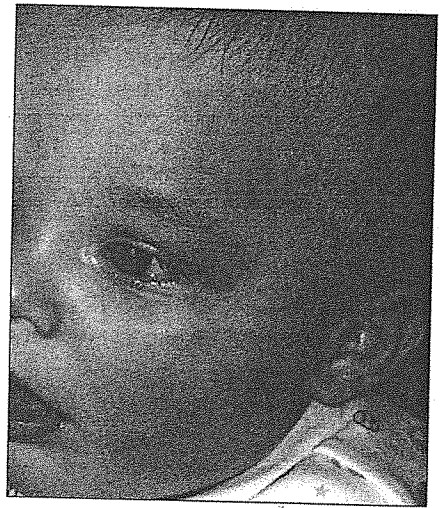


Figure 6. An 8-month-old white girl presents with an abrupt-onset fever to 101.5° F, irritability, and a unilateral flat, well-demarcated, possibly indurated, red rash on the left side of her face. (From Block,⁶ with permission)

or streptococcal pharyngitis with acute *Haemophilus conjunctivitis*.

TREATMENT OF STREPTOCOCCAL PHARYNGITIS

Why Treat with Antibiotics?

Practitioners treat GAS pharyngitis to prevent the two primary autoimmune post-streptococcal sequela: acute rheumatic fever (ARF) and acute glomerulonephritis (AGN). Both illnesses are becoming increasingly rare in the United States. Antibiotic therapy is currently perceived as not directly influencing the prevention of AGN, but it likely does prevent the spread of the nephritogenic strain. Treatment also prevents many of the suppurative complications, such as acute otitis media, perianal dermatitis (Figure 5), erysipelas (Figure 6), lymphadenitis, scalded skin syndrome, and, importantly, peritonsillar abscess. Treatment of GAS pharyngitis is widely believed to reduce duration of illness by only about a day or so,¹ but my own observation in children aged 3 to 12 years old is that symptoms rapidly resolve within 8 to 12 hours of initiating therapy. Antibiotic therapy also reduces the horizontal spread of infection within the family, day care, and school.

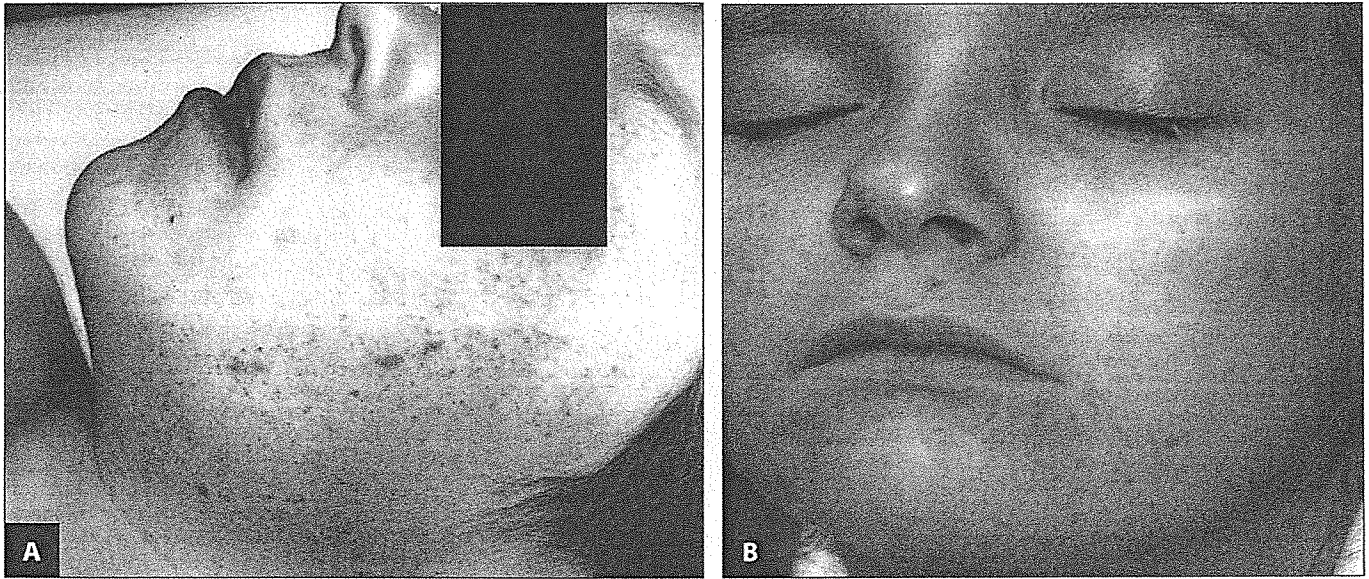


Figure 7. (A) A 5-year-old white boy who had a history of continuous fever, progressive pharyngitis, swelling of the anterior cervical lymph nodes, and decreased appetite on first examination. A rapid streptococcal test was positive. The patient developed multiple petechiae from the supraclavicular area upward. The patient was treated with oral amoxicillin and the rash and pharyngitis responded rapidly. (B) An 8-year-old white girl with a 2-day history of low-grade fever, sore throat, and anorexia. She had experienced no cough or vomiting. Her antigen detection test was positive for Group A streptococcus. Because of the significant amount of petechiae on her face, further testing was performed. Note the peri-oral and peri-orbital petechiae.

GAS Carrier State

More than 5 years ago, I had trouble grasping the concept of a pharyngeal carrier state. The literature suggested that at least 4% to 20% of asymptomatic school-aged children harbored GAS.⁸ However, when we conducted a recent GAS surveillance study as part of a longitudinal, multicenter trial, approximately 25% of asymptomatic children at our site were GAS carriers, but oddly only during that single summer time period. None were treated with antibiotics — a scary thought for one who has seen most GAS complications — and yet all GAS resolved within 3 months of the initial finding.⁷ Otherwise, during the 2-year study period, most other positive GAS tests from our site were associated with bona fide symptoms and signs of GAS pharyngitis and were treated accordingly with antibiotics.

Initial Antibiotic Therapy for GAS Pharyngitis

Except in the truly penicillin-allergic patient, amoxicillin should be the first-line therapy; my “old-school” prefer-

ence is to dose it twice daily at 40 to 60 mg/kg/day, and always for 10 days. Arguably, once-daily therapy has been sanctioned by the 2012 AAP Red Book,¹ the IDSA,² and the 2013 AAP guidelines as acceptable.³ More recent data from Clegg et al⁹ demonstrated a trend, but no statistical difference in cure rates among 652 patients treated with once-daily versus twice-daily amoxicillin (80% versus 85%). At the end of therapy, we found that amoxicillin 775 mg once daily for 7 days was comparably effective to penicillin VK for 10 days in clinical cure rates (86% versus 92%), but had worryingly low bacteriologic cure rates (65% versus 68%). These data reinforce the concept of using only 10 day therapy for amoxicillin.

Some experts would argue that because oral cephalosporins are clearly somewhat superior to the penicillins by approximately 5% to 10% in head-to-head trials, cephalosporins should supplant amoxicillin;⁸ however, I am content with an 85% cure rate for amoxicillin twice-daily as clearly demonstrated by Clegg et al.⁹ This clinical success rate

is comparable to what is expected for amoxicillin in initial therapy of acute otitis media. This approach allows the clinician to extend his antibiotic armamentarium for failures or recurrences to an additional class of antibiotics, such as the cephalosporins.

Do not repeat the ADT post-therapy, unless the child develops recurrent symptoms. This will prevent the clinician from the temptation to re-treat the asymptomatic GAS carrier state.

FIVE CAVEATS TO INITIAL ANTIBIOTIC THERAPY

- Avoid the use of macrolides, particularly short-course azithromycin. GAS resistance to macrolides ranges between 4% and 48% nationally.¹⁰ A 3-day course of azithromycin at 10 mg/kg/day has been associated with cure rates as low as 38% to 58%.^{11,12}
- Avoid the use of a single dose of 500 mg ceftriaxone. End of therapy bacteriologic failure rates have been reported as high as 54%.¹³
- Avoid the use of a single dose of benzathine penicillin. End-of-therapy

bacteriologic failure rates have been reported as high as 37%.¹³

Thus, ceftriaxone and benzathine penicillin are merely suitable injectable “starter” choices for the child who is sicker, tends to refuse medicine, or has vomiting. For either of these choices, I also highly recommend adding a supplemental 10-day course of oral amoxicillin or cephalosporin to achieve more acceptable cure rates.

- Avoid short-course antibiotic therapy, except for cefdinir, cefpodoxime, and azithromycin. These are the only three drugs that have been U.S. Food and Drug Administration (FDA)-approved for short-course, 5-day therapy for GAS pharyngitis, and for good reason. Nearly all antibiotics FDA-indicated for GAS pharyngitis have been tested with short courses; all but these three were inferior in cure rates when compared with longer-course, 10-day therapy.¹⁴

- I still use amoxicillin to treat perianal streptococcal dermatitis (Figure 5), even though failure rates as high as 32% to 43% have been reported.¹⁵ Ten days of amoxicillin-clavulanate or an oral cephalosporin were recommended instead.

GAS PHARYNGITIS ANTIBIOTIC FAILURES

No GAS resistance to penicillin has ever been documented. Rather, experts generally believe that possible causes of failure include poor adherence, previously unknown carrier state, re-infection, protection of GAS by beta lactamase-producing bacteria, and co-aggregation (or attachment of strep bacteria) to other beta-lactamase-producing organisms.³ There are data that suggest many of these failures are likely actually related to poor intestinal amoxicillin absorption rates, which has been reported to occur in as much as 10% to 15% of the pediatric population in three entirely different populations evaluated for middle ear antibiotic concentrations.¹⁶ Consequently, in my

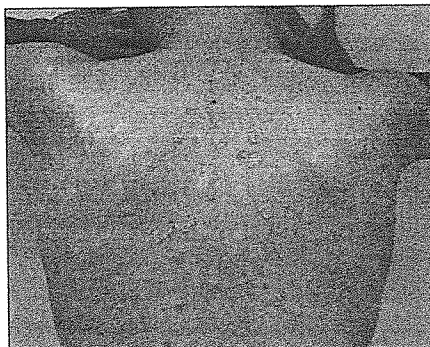


Figure 8. Multiple small, ovoid, scaly, white-to-silvery dermatitis patches mostly distributed on the back of this 9-year-old white boy about 1 week after a resolved episode of treated streptococcal pharyngitis.

practice, if a parent declares that the “darn pink stuff never works” (ie, amoxicillin) after multiple episodes of infections, I tend to believe that their child falls into this category, and I move them on to a second-line antibiotic therapy. I also use a second-line antibiotic initially for children who have received amoxicillin or any other antibiotic within the last 30 days.

ANTIBIOTIC CHOICES FOR FAILURES

First, the child who fails must not only have a positive ADT test, but they must also have signs and symptoms consistent with strep pharyngitis.

My second-line preference is to prescribe the cephalosporin class of antibiotics, particularly cephalexin (first-generation).¹⁶ Each has a generic and fairly palatable formulation. Amoxicillin-clavulanate is a suitable alternative, particularly for those more inclined to believe the beta-lactamase co-protector theory.

For the patient who has a penicillin hypersensitivity that is not “type 1,” I prefer the more expensive short-course, 5-day therapy with cefdinir or the much less palatable, less available cefpodoxime. Some experts believe that the first-generation cephalosporins — such as cephalexin, cefaclor, and cefprozil — may have too much intrinsic cross-reactivity with the penicillins and are best avoided in this scenario.¹⁷




Figure 9. A 4-year-old white boy with a peculiar, heavily vesicular, slightly pruritic rash on his hands. He also has fever, pharyngitis, lymphadenopathy, and a scarlet fever rash over his entire torso. (From Block,²⁰ with permission.)

For third-line therapy, clinicians should consider oral clindamycin (at least 20 mg/kg/day divided over three times per day); however, it is poorly palatable and expensive. Amoxicillin-clavulanate, if not used recently, is suitable. Some experts would also consider intramuscular benzathine penicillin and/or rifampin at this point.

PECULIAR SEQUELAE OF STREP PHARYNGITIS

Among white children with documented streptococcal pharyngitis, facial petechiae have been an occasional associated physical finding (Figures 7A and 7B). Most of these children have not had any cough or vomiting. But petechiae anywhere on the body of a febrile children is always cause for alarm for any clinician — particularly when worrying about a low-grade meningococcal infection or autoimmune thrombocytopenia. Thus, each of these cases must be approached quite cautiously. Additional history and physical examination should possibly include details about signs or symptoms of meningismus, arthralgias, tick bites, nosebleeds, gum bleeds, easy bruising, etc. I often prefer to perform a CBC — sometimes with a manual differential — in these cases, and I occasionally also ask for a blood culture and CMP. Careful monitoring over the next 24 to 48 hours is important if the clinician has any concerns about the level of illness.

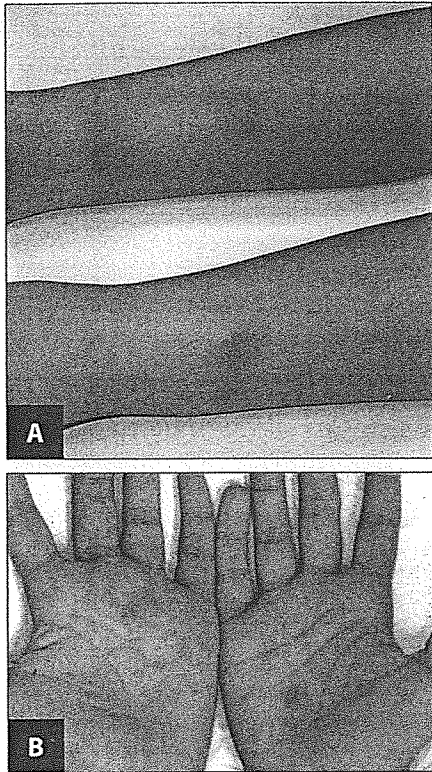


Figure 10. (A) A 13-year-old girl who developed several painful, hardened, erythematous nodules on her lower legs. She was treated for documented streptococcal pharyngitis 2 weeks prior to presentation. (B) A 15-year-old white girl with a 1 week history of painful reddened small nodules on her fingers and the palms of her hand only. She has been completely healthy in the past year, but she has been dating the same boyfriend for the past 12 months.

The boy in **Figure 8** developed a post-streptococcal guttate psoriasis. The child was re-treated with an oral cephalosporin; however, the rash did not recede for about 7 months, as is typical, even with the topical steroids and other customary psoriasis treatments. Guttate psoriasis is associated with a previous streptococcal infection in 56% to 97% of cases, some of which are perianal dermatitis-related.¹⁸

The child in **Figure 9** developed Gianotti-Crosti syndrome (GC), or papulo-vesicular acrodermatitis, related to his streptococcal pharyngitis. However, GC is most commonly associated with viral infections, particularly mono, CMV, enterovirus, and HHV6.^{19,20}

The adolescent girl in **Figure 10A**

developed a skin hypersensitivity reaction known as erythema nodosum. It mostly affects females aged older than 10 years and is most commonly associated with GAS. Occasionally it is also related to mono, tuberculosis, and inflammatory bowel disease. Thus, many experts recommend additional testing with ASO titers, monospot, chest radiograph, erythrocyte sedimentation rate, and tuberculin skin testing. The rash usually lasts 3 to 6 weeks, and approximately 90% of females develop some associated arthralgias. Although the condition most commonly occurs in the pretibial area, the other adolescent female (**Figure 10B**) developed the erythematous painful nodules on the palms of her hands. Typical of adolescent females in clinical practice, her erythema nodosum was related to oral contraceptive use, which I personally have seen as the most common cause of this condition.²⁰ The real diagnostic dilemma in these cases is how to discuss the adolescent's potential current use or future need of birth control pills in a confidential manner. ■

REFERENCES

- Hersh AL, Jackson MA, Hicks LA, Committee on Infectious Diseases. Principles of judicious antibiotic prescribing for upper respiratory tract infections in pediatrics. *Pediatrics*. 2013; 132(6):1146-1154.
- Shulman ST, Bisno AL, Clegg HW, et al. Clinical practice guideline for the diagnosis and management of group A streptococcal pharyngitis: 2012 update by the Infectious Diseases Society of America. *Clin Infect Dis*. 2012;55(10):1279-1282.
- American Academy of Pediatrics. *Red Book: 2012 Report of the Committee on Infectious Diseases*. Pickering LK, ed. 29th ed. Elk Grove Village, IL: American Academy of Pediatrics; 2012.
- Marcy SM. Update on Infectious Disease – Streptococcal Pharyngitis: Controversies in Diagnosis and Treatment. *Auto-Digest Foundation*. 2013;59(5). Available at: <http://www.audio-digest.org/CME-Series-Specials/infectious-disease>.
- Block SL. Perianal dermatitis: much more than just a diaper rash. *Pediatr Ann*. 2013;42(1):12-14.
- Block SL. The many faces of facial cellulitis. *Pediatr Ann*. 2013;42(5):187-190.
- Frenck RW. Abstract G-995. Presented at: Interscience Conference on Antimicrobial Agents and Chemotherapy 2013; September 9-13, 2013; Denver, CO.
- Casey JR, Pichichero ME. Meta-analysis of cephlosporin versus penicillin treatment of group A streptococcal tonsillopharyngitis in children. *Pediatrics*. 2004;113(4):866-882.
- Clegg HW, Dallas SD, Roddey OF, et al: Extrapharyngeal group A Streptococcus infection: diagnostic accuracy and utility of rapid antigen testing. *Pediatr Infect Dis J*. 2003;22(8):726-731.
- Martin JM, Green M, Barbadora KA, Wald ER. Erythromycin-resistant group A streptococci in schoolchildren in Pittsburgh. *N Engl J Med*. 2002;346(16):1200-1206.
- Cohen R, Reinert P, De La Rocque F, et al. Comparison of two dosages of azithromycin for three days versus penicillin V for ten days in acute group A streptococcal tonsillopharyngitis. *Pediatr Infect Dis J*. 2002;21(4):297-303.
- Schaad UB, Kellerhals P, Altwegg M, Swiss Pharyngitis Study Group. Azithromycin versus penicillin V for treatment of acute group A streptococcal pharyngitis. *Pediatr Infect Dis J*. 2002;21(4):304-308.
- Kaplan EL, Johnson DR. Unexplained reduced microbiological efficacy of intramuscular benzathine penicillin G and of oral penicillin V in eradication of group a streptococci from children with acute pharyngitis. *Pediatrics*. 2001;108(5):1180-1186.
- Block SL. Short-course antimicrobial therapy of streptococcal pharyngitis. *Clin Pediatr (Phila)*. 2003;42(8):663-671.
- Olson D, Edmonson MB. Outcomes in children treated for perineal group A beta-hemolytic streptococcal dermatitis. *Pediatr Infect Dis J*. 2011;30(1):933-936.
- Block SL, Harrison CJ. *Diagnosis and Management of Acute Otitis Media*. 3rd ed. Caddo, OK: Professional Publications, Inc. 2005.
- DePestel DD, Benninger S, Danziger L, et al. Cephalosporin use in treatment of patients with penicillin allergies. *J Am Pharm Assoc (2003)*. 2008;48(4):530-540.
- Mehlis S. Guttate psoriasis. UpToDate website. <http://www.uptodate.com/contents/guttate-psoriasis>.
- Paller AS, Mancini AJ, eds. *Hurwitz Clinical Pediatric Dermatology: A Textbook of Skin Disorders of Childhood and Adolescence*. 3rd ed. Philadelphia, PA: Elsevier/Saunders; 2006.
- Block SL. Management of a digital world: from felons to fungus. *Pediatr Ann*. 2013;42(7):271-274.